Otology & Neurotology
00:00–00 © 2014, Otology & Neurotology, Inc.

Chemically Assisted Dissection by Means of Mesna in Cholesteatoma Surgery

*Vincenzo Vincenti, †Jacques Magnan, *Maria Silvia Saccardi, and ‡Carlo Zini

**Unit of Audiology and Pediatric Otorhinolaryngology, Department of Clinical and Experimental Medicine, University of Parma, Parma, Italy; †Service d'Oto-Rhino-Laryngologie et Chirurgie Cervico-Faciale, Hôpital Nord-Chemin des Bourrelly, Marseille, France; and ‡Area of Otolaryngology, Rome American Hospital, Rome, Italy*

Objective: To investigate whether the use of mesna (sodium 2-mercaptoethanesulfonate), a mucolytic agent capable of breaking disulfur bonds, reduces the frequency of residual cholesteatoma in canal wall up tympanomastoidectomy.
Study Design: Retrospective study.
Setting: Tertiary care otology and skull base centers.
Patients: Two hundred fourteen patients operated on by means of canal wall up tympanomastoidectomy for a middle ear cholesteatoma.
Interventions: Planned staged canal wall up tympanomastoidectomy. In the study group, the cholesteatoma removal was performed with the support of chemically assisted dissection by using mesna. In the control group, the dissection of the disease was performed by means of a traditional mechanical technique alone.
Main Outcome Measures: Prevalence of residual cholesteatoma at the second-stage operation in the 2 groups of study.
Results: One hundred eight patients were treated with the ancillary use of mesna and one hundred six without chemically assisted dissection. A residual cholesteatoma was found in 12 (11.1%) of the 108 patients treated with chemically assisted dissection and in 26 (24.5%) of the 106 patients treated with mechanical dissection. After adjusting for potential confounders, CADISS procedure was associated with a significantly lower risk of having residual cholesteatoma (OR, 0.39; 95% CI, 0.18–0.84, $p = 0.02$).
Conclusion: This study showed that chemically assisted dissection by using mesna represents a valid support in reducing the frequency of residual disease in cholesteatoma surgery.

The primary goals of cholesteatoma surgery comprise total eradication of the disease, hearing restoration, and minimizing the risk of recidivism.

Historically, the surgical approaches for the treatment of cholesteatoma are broadly split into 2 categories: the canal wall down and the canal wall up procedure. The open technique generally leads to a lower rate of recurrence, but it is accused of losing the self-cleansing ability of the ear with consequent recurrent episodes of otorrhea. Conversely, the closed technique respects the middle ear anatomy and maintains the shape of the external auditory canal with normal skin migration but results in a higher rate of recurrence. Since 1974, we have constantly used staged canal wall up mastoidectomy in the surgical management of middle ear cholesteatoma; over the years, we tried to improve the surgical technique to reduce the incidence of both residual and recurrent cholesteatoma (1–4). Unlike recurrent cholesteatoma that originates from a new postoperative retraction pocket, residual cholesteatoma develops from epidermal debris left behind from surgery with an incidence ranging from 10% to 43% (5).

The likelihood of inadvertently leaving epidermal debris in place is higher in several particular circumstances: first, in presence of cholesteatomas, interesting middle ear regions that are difficult to access under otomicroscopy, such as anterior epitympanum and sinus tympani (6), and second, when the cholesteatoma must be dissected away from either intact ossicular chain, or labyrinthine fistula, or exposed facial nerve or bony defect of the middle cranial fossa (7). In these situations, the dissection must be gentle enough to avoid injuries to the above-mentioned structures, but it could be inadequately sufficient for a complete and accurate removal of the disease.

Over the years, various technological innovations have been proposed to reduce the incidence of the residual cholesteatoma: otoendoscopy, to better visualize and clean the ''blind'' areas in the middle ear (8); the KTP laser that should allow a more gentle and accurate dissection (9); and the utilization of the galectin-7 to identify

Address correspondence reprint requests to Vincenzo Vincenti, M.D., Unit of Audiology Pediatric Otorhinolaryngology, Department of Clinical Experimental Medicine, University of Parma, Via Gramsci 14 – 43126 Parma, Italy, E-mail: vincenzo.vincenti@unipr.it
The authors disclose no conflicts of interest.
Financial disclosure: None

Copyright © 2014 Otology & Neurotology, Inc. Unauthorized reproduction of this article is prohibited.

microscopic epidermal residues with an immunofluorescent method (10). Alternative surgical approaches also have been proposed (11,12).

We pursued the goal of a more accurate removal of cholesteatoma searching for a substance that would facilitate its dissection. Starting from the hypothesis that adhesions between pathologic and healthy tissues are rich in disulfide bonds, we started a research project entitled ''Chemically Assisted Dissection'' (CADISS). Among various substances, we chose sodium 2-mercaptoethanesulfonate (mesna), a substance already used in medicine for its mucolytic, antioxidant, and protective properties and capable of breaking disulfur bridges (13,14). To examine critically the effect of CADISS by using mesna on the rate of residual cholesteatoma, we performed a comparison between a group of 108 patients treated with CADISS and a group of 106 patients treated with traditional mechanical dissection alone. This review was specifically limited to adult patients with middle ear cholesteatoma operated on by planned staged canal wall up tympanomastoidectomy.

MATERIALS AND METHODS

The aim of the study was to verify whether the ancillary use of CADISS by using mesna can reduce the residual disease rate in patients with primary acquired middle ear cholesteatoma. To this purpose, a retrospective analysis of the surgical reports of all patients with middle ear cholesteatoma operated on with the support of CADISS by the senior authors (C. Z. and J. M.) between January 2009 and December 2011 was performed. The control group consisted of all cholesteatomas operated on in the 2 previous years by the same surgeons using the traditional mechanical technique alone. The institutional review boards approved this study and the review of medical records pertaining to this study. Inclusion criteria for both groups were as follows: adult age (≥18 yr), fresh cholesteatoma with no history of ipsilateral previous ear surgery, and surgical treatment consisting in planned staged canal wall up tympanomastoidectomy. Exclusion criteria were as follows: pediatric age (<18 yr), congenital cholesteatoma, recurrent cholesteatoma, one-stage surgery, canal wall down mastoidectomy, and observation of a postoperative retraction pocket between the 2 surgical stages.

According to Tos classification (15), cholesteatomas were divided into the following: 1) attic cholesteatoma, originating from the Shrapnell's membrane and extending primary into the attic; and 2) pars tensa cholesteatoma, originating from both the posterosuperior retraction of the pars tensa and extending primary into the tympanic sinuses (sinus cholesteatoma) or an entirely retracted pars tensa (tensa retraction cholesteatoma). The extent of the disease was defined by the number of sites involved with cholesteatoma, according to Saleh and Mills classification (16). Based on intraoperative involvement of the attic, antrum, mastoid cavity, mesotympanum, Eustachian tube, labyrinth, and middle cranial fossa, cholesteatoma was classified as Stage I (1 site), Stage II (2 sites), Stage III (3 sites), Stage IV (4 sites), and Stage V (5 or more sites).

In all cases, the first-stage operation consisted in the exposure of the bony external canal and mastoid by using a retroauricular approach, mastoidectomy, atticotomy, and posterior tympanotomy. The removal of the cholesteatoma was performed using a combined (transcanal-transmastoid) approach. At the beginning of surgery, 10% mesna solution was obtained using saline and drawn into a syringe. Once exposed, the cholesteatoma, before starting the removal, a small amount of mesna solution was injected and left into the middle ear and the mastoid for 3 minutes. Successively, during the surgical dissection, mesna was topically administered with continuous instillation by means of microdissectors delivering the substance directly from their tips (Fig. 1). At the end of the disease extirpation, small micromirrors or 30- or 70-degree angled endoscopes were used to control the quality of excision. Location and extension of the disease were systematically recorded in surgical reports.

The second-stage procedure was performed not before 12 months after the first-stage operation using the same facial recess approach created during the primary surgery. Exploration of all the cavities of the middle ear and mastoid was performed using the combined technique as in the first surgical step. Residual cholesteatoma was defined as a collection of squamous epithelium found in the middle ear or mastoid cavity developed from the epidermal debris inadvertently left in place from the first stage of surgery. The frequency and location of the residual cholesteatoma were then compared between the 2 groups of study. For descriptive purpose, the baseline characteristics of the 2 groups were compared using a χ^2 test and ANOVA model for categorical and continuous variables, respectively. Bivariate tests were used: chi-square for dichotomic variables was used to test the significance of categorical covariates. Parametric (ANOVA) and nonparametric tests (Kruskal-Wallis, median test, and Mann–Whitney *U* test) were used to test the significance of continuous covariates. Logistic regression analysis was used to examine the effect on the residual cholesteatoma of mesna (CADISS group) compared with the traditional mechanical technique alone, after adjusting for multiple confounders. Associations between the presence versus absence of residual disease at second-stage procedure and variables of interest, including patient age, cholesteatoma type, disease stage, and ossicular chain status, were evaluated using Fisher exact tests.

Statistical analysis was carried out using SAS 8.2 version statistical software. The results with a value of $p < 0.05$ were considered significant.

RESULTS

Two hundred fourteen patients were included in the study, 108 operated on with the ancillary use of mesna

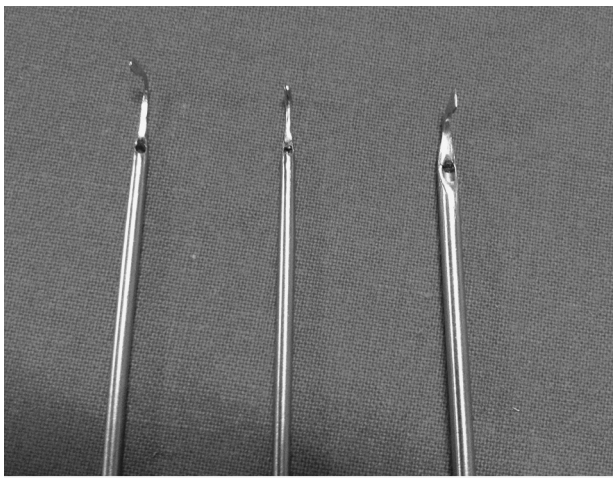

FIG. 1. Details of surgical instruments used in chemically assisted dissection.

Copyright © 2014 Otology & Neurotology, Inc. Unauthorized reproduction of this article is prohibited.

(CADISS group) and 106 treated with the traditional mechanical technique alone (no CADISS group).

The CADISS group included 58 women and 50 men with a mean age at first-stage operation of 45 years (range, 18–69 yr). The no CADISS group included 61 women and 45 men with a mean age at first-stage operation of 43 years (range, 18–72 yr). The time interval between the first and the second procedure ranged from 12 to 15 months, with an average of 12.75 months in the CADISS group and 12.63 months in the no CADISS group. The allocation of the various types of cholesteatoma in the 2 study groups is described in Table 1.

Overall, during the second-look procedure, 176 patients (82.25%) were free of disease; 38 patients were found to have a residual cholesteatoma, representing an overall rate of 17.75%. When analyzing the 2 groups separately, 12 (11.1%) of the 108 patients operated with the support of CADISS were observed to have residual disease; in the group of 106 patients treated without CADISS, 26 (24.5%) presented with a residual cholesteatoma. In unadjusted analysis, the difference between the 2 groups was statistically significant ($p = 0.02$) (Fig. 2).

To exclude any factor that may have biased the results, the baseline features of the 2 groups were compared. No significant differences were observed on the basis of the parameters of sex, age, cholesteatoma location and extension, ossicular chain lysis, erosion of the Fallopian canal, labyrinthine fistula, or bony defects of the middle cranial fossa (Table 2). While analyzing prevalence according to the middle ear regions involved by the disease, we noted that the incidence of residual cholesteatoma dropped from 15.8% (no CADISS group) to 5.8% (CADISS group) in attic cholesteatomas and from 37.2% (no CADISS group) to 20% (CADISS group) in pars tensa cholesteatomas (Tables 3 and 4). Similarly, in the presence of an intact ossicular chain, the incidence of residual cholesteatoma dropped from 6 cases of 12 (no CADISS group) to 1 of 10 (CADISS group).

No residual cholesteatomas were found in presence of labyrinthine fistula (6 cases), epidermization of an exposed facial nerve (6 cases), or bony defect of the middle cranial fossa (5 cases) in patients treated with the support of CADISS; on the other hand, 3 residual cholesteatomas (1 of 5 patients with a labyrinthine fistula, 1 of 4 with an epidermizated facial nerve, and 1 of 4 with a bony defect of the middle cranial fossa) were observed in patients treated with traditional mechanical dissection alone.

TABLE 1. *Cholesteatoma type according to Tos classification (14)*

Cholesteatoma type*	CADISS (n = 108)	No CADISS (n = 106)
Attic cholesteatoma	68 (63.0%)	63 (59.4%)
Sinus cholesteatoma	35 (32.4%)	40 (37.7%)
Tensa-retraction cholesteatoma	5 (4.6%)	3 (2.9%)
	Total = 108	Total = 106

*p = NS between the 2 groups (Manten-Haenszel chi square).

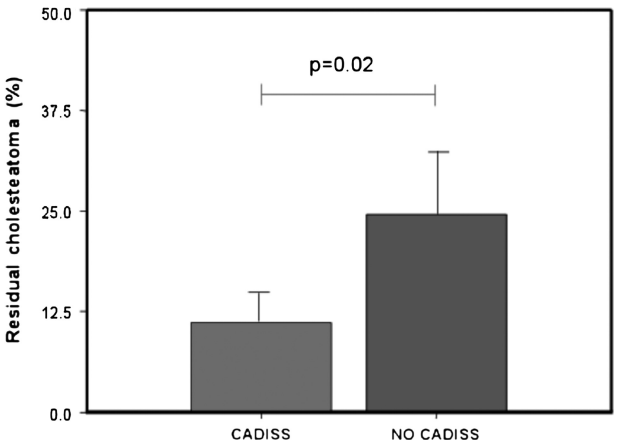

FIG. 2. Residual cholesteatoma percentage across the 2 groups of study.

Regarding size and aspect of the residual disease, in the CADISS group, the lesions had a cystic appearance in all cases with a mean size of 2.60 mm; in the no CADISS group, residual cholesteatoma had a cystic appearance (mean size, 3.40 mm) in 22 cases, whereas in 4 patients, it was represented by free matrix infiltrating the surrounding structures.

After adjusting for potential confounders, CADISS procedure was associated with a significantly lower risk of having residual cholesteatoma (OR, 0.39; 95% CI, 0.18–0.84, $p = 0.02$) (Table 5). The patients with more advanced initial disease (Stages 4 and 5) and pars tensa cholesteatoma had a higher residual cholesteatoma rate.

DISCUSSION

One of the unsolved problems of canal wall up techniques is the high frequency of residual cholesteatoma, especially in regions that are difficult to access with otomicroscopy. The use of otoendoscopes as an adjunct to operating microscope has led to a decrease of the residual

TABLE 2. *Baseline clinical characteristics of patients*

	CADISS group (n = 108)	No CADISS group (n = 106)	p*
Age (yr) (mean ± SD)	45.02 ± 16.1	43.1 ± 15.3	0.37
Women (n)	58	61	0.48
Cholesteatoma in advanced stage (Stages 4 and 5) (n)	36	28	0.34
Intact ossicular chain (n)	10	12	0.62
Eroded incus (n)	92	91	0.89
Eroded stapes (n)	43	39	0.55
Epidermization of the facial nerve (n)	6	4	0.54
Labyrinthine fistula (n)	6	5	0.84
Bony defect of middle cranial fossa (n)	5	4	0.75

*Manten-Haenszel chi square for parametric variables and Kruskal-Wallis for nonparametric variables.

Copyright © 2014 Otology & Neurotology, Inc. Unauthorized reproduction of this article is prohibited.

TABLE 3. *Residual disease in attic cholesteatoma*

	CADISS		NO CADISS	
Cholesteatoma stage	No. of cases	Residual cholesteatoma (n)	No. of cases	Residual cholesteatoma (n)
S1	19	0	21	1
S2	12	0	15	1
S3	14	1	11	3
S4	18	2	14	4
S5	5	1	2	1
	Total = 68	Total = 4 (5.8%)	Total = 63	Total = 10 (15.8%)

*p = 0.03 between the 2 groups (Manten-Haenszel chi square).

cholesteatoma incidence, which has allowed surgeons to detect and remove the disease from the blind pockets of the middle ear (6,17). In a study on 113 patients with a middle ear cholesteatoma treated by a canal wall up technique, Gaillardin et al. (18) have observed a residual cholesteatoma in 25% of the series as a whole, in 45% of cholesteatomas involving the medial attic, and in 20.5% of retrotympanic cholesteatomas, despite the use of otoendoscopy. Reporting on prevalence of residual cholesteatoma in 4 different types of mastoid surgery performed using otoendoscopy in conjunction with the microscope, Yung (19) has identified a residual cholesteatoma in 9.45% of patients operated on by a closed cavity mastoidectomy and in 8.7% of patients treated with an open cavity mastoidectomy. Overall, the incidence of residual disease was 8.2% and reached 10.5% in cholesteatomas extending into the sinus tympani. Yung (19) concluded that the use of otoendoscopes cannot guarantee the elimination of the residual disease and advocated the development of new surgical techniques to clean up the cholesteatoma bed. To improve intraoperative exposure of the middle ear and mastoid without creating a mastoid bowl, Haginomori et al. (11) and Gantz et al. (12) proposed an alternative surgical technique consisting in removing the posterior wall of the external auditory canal and its subsequent reconstruction. Hoginomori et al. (11) have reported an incidence of 21% in a series of 85 cholesteatomas operated on by canal wall down tympanoplasty with soft-wall reconstruction, whereas Gantz et al. (12) have observed a residual cholesteatoma in 10 (9.8%) of 102 patients operated on by canal wall reconstruction tympanomastoidectomy.

Indeed, residual cholesteatoma is often observed in easily accessible and controllable areas. The cause of such residua is not an insufficient surgical view but rather an incomplete cleaning of the matrix; typical examples are cholesteatomas remaining around the ossicles or on bony defects of the middle cranial fossa, labyrinth, and Fallopian canal. Under these circumstances, surgical dissection has to be gentle enough to avoid iatrogenic lesions; however, the risk of incomplete removal of the disease is heightened. Other risk factors for the development of a residual cholesteatoma due to a demanding dissection are the infiltration of the matrix to the pneumatized mastoid cavity, the middle ear mucosa replaced by matrix, and the presence of polypoidal mucosa (20). To improve surgical dissection in such cases, Hamilton (9) proposed the KTP laser, which allows surgeon to remove the disease by replacing mechanical dissection with tissue vaporization. In a controlled, nonrandomized, prospective study on 68 cholesteatomas operated on by staged canal wall up technique, Hamilton (9) reported the presence of residua in 1 of 35 patients treated with the ancillary use of KTP laser and in 10 of 33 patients treated without the laser.

Our approach has been to make the cholesteatomatous matrix removal easier in combining mechanical with chemical dissection by means of a substance capable to dissolve adhesions between pathologic and normal tissues. Because the cholesteatomatous matrix is largely made of keratin, a protein rich in disulfide bonds, we searched for a chemical product capable of breaking these bonds. After trying different substances, we chose mesna, a synthetic sulfur compound that belongs to a class of thiol products already used in medicine for its mucolytic, antioxidant, and protective properties. Intraoperative use of mesna as a chemical dissector has been reported in different surgical fields such as gynecology, orthopedics, and otorhinolaryngology (14,21,22). Mesna was used by Yilmaz et al. (23) to

TABLE 4. *Residual disease in sinus and tensa-retraction cholesteatoma*

	CADISS		NO CADISS	
Cholesteatoma stage	No. of cases	Residual cholesteatoma (n)	No. of cases	Residual cholesteatoma (n)
S1	10	0	11	2
S2	7	1	12	3
S3	10	2	8	2
S4	8	2	9	3
S5	5	3	3	3
	Total = 40	Total = 8 (20%)	Total = 43	Total = 16 (37.2%)

*p = 0.02 between the 2 groups (Manten-Haenszel chi square).

Copyright © 2014 Otology & Neurotology, Inc. Unauthorized reproduction of this article is prohibited.

TABLE 5. *Logistic regression analysis testing the effect on the residual cholesteatoma of mesna (CADISS group) versus the traditional mechanical technique alone, after adjusting for multiple confounders*

	OR	95% CI	*p*
CADISS versus traditional mechanical technique	0.39	(0.18–0.84)	0.02
Cholesteatoma in advanced stage (S4, S5)	1.16	(0.46–2.91)	0.74
Age	1.01	(0.98–1.03)	0.88
Women versus men	0.93	(0.43–1.98)	0.85
Intact ossicular chain	5.42	(0.48–61.90)	0.17
Incus eroded	2.40	(1.03–5.59)	0.04
Stapes eroded	1.87	(0.21–16.90)	0.58
Epidermizated facial nerve	0.43	(0.05–3.86)	0.45
Labyrinthine fistula	0.51	(0.06–4.74)	0.56
Bony defect of middle cranial fossa	2.26	(0.46–11.01)	0.31

facilitate surgery in atelectatic ears and adhesive otitis media. The authors (23) stated that mesna makes the operation easier and safer by allowing lysis of adhesions between the middle ear mucosa and the tympanic membrane through its mechanical and chemical properties. The aim of this study was to investigate whether the use of mesna reduces the frequency of residual disease, making the removal of middle ear cholesteatoma more accurate. For this purpose, we analyzed retrospectively the rate of residual cholesteatoma in a population of patients, all operated on by the same surgical technique, that is, planned canal wall up tympanomastoidectomy; in 108 patients, surgery was performed with the ancillary use of CADISS by means of mesna (CADISS group), whereas 106 patients were treated with the traditional mechanical technique alone (no CADISS group).

Because retrospective studies can be biased by an irregular distribution of the patients in the study groups, we performed a statistical analysis that excluded significant differences between the 2 groups on the basis of the parameters of sex, age, cholesteatoma location and extension, ossicular chain lysis, erosion of the Fallopian canal, labyrinthine fistula, or bony defects of middle cranial fossa. Overall, the analysis of our results showed a statistically significant reduction of the residual cholesteatoma frequency in the CADISS group compared with the no CADISS group. A decrease of the residual disease incidence in the CADISS group was observed in both attic and pars tensa cholesteatoma. The same conclusions were reached by Kalcioglu et al. (24) in a recent report on effectiveness of mesna in cholesteatoma surgery. The authors noted a statistically significant decrease of the residual disease rate by using mesna in both canal wall down and canal wall up tympanoplasty. Mesna has proven especially useful in cholesteatomas with an intact ossicular chain; furthermore, mesna allowed the incidence of residual cholesteatoma to be reduced also in the presence of labyrinthine fistula and epidermization of an exposed facial nerve or bony defect of the middle cranial fossa. Finally, the absence in both groups of major complications, such as sensorineural hearing loss, facial paralysis, and meningitis, demonstrates that intraoperative use of mesna is safe and does not lead to toxic effects on middle and inner ear structures.

CONCLUSIONS

Despite intraoperative use of otoendoscope, residual cholesteatoma remains an open problem, especially in canal wall up technique. Chemically assisted dissection by means of mesna can be a safe, inexpensive, and effective support to further reduce the incidence of residual disease in cholesteatoma surgery. Multicenter and prospective studies with a higher number of patients are needed to validate this technique.

Acknowledgments: The authors thank Fulvio Lauretani for the analysis of the data while working at the Learning Center for Health Systems and Health Services Organization.

REFERENCES

1. Zini C, Bacciu S, Pasanisi E. Recurrent cholesteatoma after combined approach tympanoplasty: pathogenesis and prevention. *Rev Laryngol Otol Rhinol (Bord)* 1991;112:11–6.
2. Zini C, Sanna M, Scandellari R, Jemmi G. Residual and recurrent cholesteatoma in closed tympanoplasty. *Am J Otol* 1984;5:277–82.
3. Bacciu A, Pasanisi E, Vincenti V, Di Lella F, Bacciu S. Reconstruction of outer attic wall defects using bone patè: long-term clinical and histological evaluation. *Eur Arch Otorhinolaryngol* 2006; 263:983–7.
4. Vincenti V, Marra F, Bertoldi B, et al., Acquired middle ear cholesteatoma in children with cleft palate: experience from 18 surgical cases. *Int J Pediatr Otorhinolaryngol* 2014; http://dx.doi.org/10.1016/j.ijporl.2014.03.007.
5. Sheehy JL, Brackmann DE, Graham MD. Cholesteatoma surgery: residual and recurrent disease: a review of 1,024 cases. *Ann Otol Rhinol Laryngol* 1977;86:451–62.
6. Badr-el-Dine M. Value of ear endoscopy in cholesteatoma surgery. *Otol Neurotol* 2002;23:631–5.
7. Robinson JM. Cholesteatoma: skin in the wrong place. *J R Soc Med* 1997;90:93–6.
8. Marchioni D, Villari D, Mattioli F, Alicandri-Ciufelli M, Piccinini A, Presutti L. Endoscopic management of attic cholesteatoma: a single-institution experience. *Otolaryngol Clin North Am* 2013; 46:201–9.
9. Hamilton JW. Efficacy of the KTP laser in the treatment of middle ear cholesteatoma. *Otol Neurotol* 2005;26:135–9.
10. Takagi D, Hato N, Okada M, et al., Galectin-7 as a marker of cholesteatoma residue and its detection during surgery by an immunofluorescent method – a preliminary study. *Otol Neurotol* 2012; 33:396–9.
11. Haginomori S, Takamaki A, Nonaka R, Takenaka H. Residual cho lesteatoma: incidence and localization in canal wall down tympanoplasty with soft-wall reconstruction. *Arch Otolaryngol Head Neck Surg* 2008;134(6):652–7.
12. Gantz B, Wilkinson EP, Hansen MR. Canal wall reconstruction tympanomastoidectomy with mastoid obliteration. *Laryngoscope* 2005;115:1734–40.
13. Vincenti V, Mondain M, Pasanisi E, et al., Cochlear effects of Mesna application into the middle ear. *Ann NY Acad Sci* 1999; 28:425–32.
14. Casale M, Di Martino A, Salvinelli F, Trombetta M, Denaro V. Mesna for chemically assisted tissue dissection. *Expert Opin Investig Drugs* 2010;19:699–707.
15. Tos M. Incidence, etiology and pathogenesis of cholesteatoma in childhood. In: *Adv Otorhinolaryngol Pediatr Otol*. Basel: Karger, 1988:110–7.

Copyright © 2014 Otology & Neurotology, Inc. Unauthorized reproduction of this article is prohibited.

16. Saleh HA, Mills RP. Classification and staging of cholesteatoma. *Clin Otolaryngol* 1999;24:355–9.
17. Marchionni D, Alicandri-Ciufelli M, Piccinini A, Genovese E, Presutti L. Inferior retrotympanum revisited: an endoscopic anatomic study. *Laryngoscope* 2010;120:1880–6.
18. Gaillardin L, Lescanne E, Moriniere S, Cottier JP, Robier A. Residual cholesteatoma: prevalence and location. Follow-up strategy in adults. *Eur Ann Otolaryngol Head Neck Dis* 2012;129:136–40.
19. Yung MW. The use of the middle ear endoscopy: has residual cholesteatoma been eliminated?. *J Laryngol Otol* 2001;115:858–961.
20. Gristwood RE, Venables WN. Factors influencing the probability of residual cholesteatoma. *Ann Otol Rhinol Laryngol* 1990; 99:120–3.
21. Benassi L, Lopopolo G, Pazzoni F, et al., Chemically assisted dissection of tissues: an interesting support in abdominal myomectomy. *J Am Coll Surg* 2000;191:65–9.
22. Denaro V, Di Martino A, Longo UG, et al., Effectiveness of a mucolytic agent as a local adjuvant in revision lumbar spine surgery. *Eur Spine J* 2008;17:1752–56.
23. Yilmaz M, Goksu N, Bayramoglu I, Bayazit YA. Practical use of Mesna in atelectatic ears and adhesive otitis media. *ORL J Otorhinolaryngol Relat Spec* 2006;68:195–8.
24. Kalcioglu MT, Cicek M, Bayindir T, Ozdamar OI. Effectiveness of Mesna on the success of cholesteatoma surgery. *Am J Otolaryngol Head Neck Med Surg* 2013; http://dx.doi.org/10.1016/j.amjoto.2014.01.002.

Copyright © 2014 Otology & Neurotology, Inc. Unauthorized reproduction of this article is prohibited.